

Intrastromal corneal ring segments and posterior chamber phakic intraocular lens implantation for keratoconus correction

José F. Alfonso, MD, PhD, Carlos Lisa, MD, Luis Fernández-Vega, MD, PhD, David Madrid-Costa, OD, MSc, PhD, Arancha Poo-López, OD, Robert Montés-Micó, PhD

PURPOSE: To evaluate the efficacy, safety, and predictability of sequential implantation of Keraring intrastromal corneal ring segments (ICRS) and an Implantable Collamer Lens phakic intraocular lens (pIOL) with corneal relaxing incisions for refractive correction of keratoconus.

SETTING: Fernández-Vega Ophthalmological Institute, Oviedo, Spain.

DESIGN: Cohort study.

METHODS: This study comprised patients with keratoconus who had ICRS implantation followed 6 months later by pIOL implantation with corneal relaxing incisions. The uncorrected (UDVA) and corrected (CDVA) distance visual acuities and residual refractive errors, analyzed using vector analysis, were recorded preoperatively, 6 months after ICRS implantation, and 6 months after pIOL implantation.

RESULTS: The study enrolled 40 eyes (31 patients). The mean UDVA (decimal) was 0.11 Snellen \pm 0.05 (SD) preoperatively, 0.18 \pm 0.14 Snellen 6 months after ICRS implantation ($P = .001$), and 0.50 \pm 0.27 Snellen 6 months after pIOL implantation ($P < .0001$). The mean CDVA was 0.56 \pm 0.23 Snellen, 0.68 \pm 0.25 Snellen, and 0.73 \pm 0.20 Snellen, respectively (all $P < .0001$). Six months after pIOL implantation, the efficacy index was 0.88 and the safety index, 1.28. At 6 months, 65% of eyes were within ± 1.00 diopter (D) of the desired refraction and 45% were within ± 0.50 D. The mean spherical equivalent after pIOL implantation was -1.19 ± 1.33 D.

CONCLUSION: Sequential ICRS and pIOL implantation plus corneal relaxing incisions provided good visual and refractive outcomes, indicating that it is a predictable procedure for refractive correction of keratoconus.

Financial Disclosure: No author has a financial or proprietary interest in any material or method mentioned.

J Cataract Refract Surg 2011; 37:706–713 © 2011 ASCRS and ESCRS

Keratoconus is a progressive noninflammatory disorder in which the cornea assumes a conical shape. The corneal thinning induces irregular astigmatism, myopia, and protrusion, leading to a mild to severe decrease in the quality of vision.^{1,2} Recent studies have shown that intrastromal corneal ring segment (ICRS) implantation with femtosecond laser tunnel creation is an effective method for improving the shape of the cornea, thus reducing astigmatism and corneal higher-order aberrations (HOAs) in patients with clear corneas and contact lens intolerance.^{3–7}

Previous studies^{5–7} report that ICRS implantation with femtosecond laser tunnel creation is a minimally invasive procedure for improving visual acuity in

patients with keratoconus. However, many eyes with keratoconus have high myopia. Although the corneal shape in these eyes may improve after ICRS implantation, most patients require contact lenses or spectacles to correct the residual refractive error. A recent study⁸ found that implantation of a phakic intraocular lens (pIOL) was a safe, effective, and predictable way to correct myopia associated with keratoconus.

In this study, we evaluated eyes with keratoconus that had sequential Keraring ICRS (Mediphacos Ltd.) implantation followed by Visian Implantable Collamer Lens posterior chamber pIOL (Staar Surgical) implantation with corneal relaxing incisions for the refractive correction of keratoconus. To our

knowledge, this is the first study to evaluate this procedure using these 2 devices.

PATIENTS AND METHODS

This prospective study included eyes with keratoconus that had sequential ICRS implantation and pIOL implantation plus corneal relaxing incisions at Fernández-Vega Ophthalmological Institute, Oviedo, Spain. The tenets of the Declaration of Helsinki were followed, and full ethical approval from the institute was obtained. After receiving a full explanation of the nature and possible consequences of the study and surgery, all patients provided informed consent.

Inclusion criteria were keratoconus, contact lens intolerance, a clear cornea, maximum keratometry (K) reading less than 55.0 diopters (D), minimum K reading more than 40.0 D, and minimum corneal thickness more than 400 μm . In addition, the differences between the axis of the refractive cylinder and the axis of the corneal cylinder measured with a Javal keratometer and with an Orbscan IIz topographic system (Bausch & Lomb) had to be less than 30 degrees. Exclusion criteria included previous corneal or intraocular surgery, history of herpetic keratitis, diagnosed autoimmune disease, systemic connective tissue disease, anterior chamber depth (ACD) less than 3.0 mm, endothelial cell density less than 2000 cells/ mm^2 , cataract, history of glaucoma or retinal detachment, macular degeneration or retinopathy, neuro-ophthalmic disease, and history of ocular inflammation.

Intrastromal Segments and Intraocular Lens

All eyes in the study received Keraring ICRS. These Ferrara-type ICRS are poly(methyl methacrylate) with a triangular cross-section that induces a prismatic effect on the cornea. The apical diameter of the ICRS is 5.0 mm, and the flat basis width is 0.6 mm with variable thickness (0.15 mm to 0.30 mm with 0.50 mm steps) and arc lengths (90 degrees, 120 degrees, 160 degrees, 210 degrees).

A Visian Implantable Collamer Lens pIOL was used in all cases. This posterior chamber pIOL is of a collagen copolymer material and is intended to correct myopia.

Preoperative Examination

Before ICRS surgery and after pIOL implantation, patients had a complete ophthalmologic examination including uncorrected distance visual acuity (UDVA), corrected distance visual acuity (CDVA), manifest and cycloplegic refractions, keratometry (K), corneal topography, endothelial cell count, pachymetry, slitlamp microscopy, Goldmann

applanation tonometry, and binocular indirect ophthalmoscopy through a dilated pupil. The ACD was measured using anterior segment optical coherence tomography (Visante, Carl Zeiss Meditec AG). Contact lens use was discontinued 6 months before corneal topography was performed. Diagnosis of keratoconus was established by the combination of computerized videokeratography of the anterior and posterior corneal surfaces (Orbscan IIz), K readings, and corneal pachymetry.⁹⁻¹² All eyes had an inferior-superior corneal shape index greater than 1.40 D (from a mean of 5 points with 30-degree intervals located 3.0 mm from center).²

Surgical Technique

Intrastromal Segments The decision to implant the ICRS was made according to the manufacturer's nomogram. One or 2 segments were implanted based on the distribution of the ectatic area on the corneal surface. The thickness of the segment was decided based on the distribution of the ectatic area and the spherical equivalent (SE).⁵⁻⁷ The same surgeon (J.F.A.) performed all ICRS implantation procedures using topical anesthesia. Preoperative medications included proparacaine 0.5%, ciprofloxacin 0.3%, and oxybuprocaine CIH 0.2%. After the center of the pupil was marked and corneal thickness at the area of the implantation (5.0 mm diameter) was measured by ultrasonic pachymetry, a disposable suction ring was placed and centered with respect to the pupil center.

A tunnel was created at 80% corneal thickness using a 60 KHz femtosecond laser (IntraLase, IntraLase, Inc.). This infrared neodymium glass femtosecond laser has a wavelength of 1053 nm. The laser beam, which has a 3 μm diameter (spot size), is optically focused at a predetermined intrastromal depth by computer scanners, which give a focus (dissection) range between 90 μm and 400 μm from the corneal anterior surface. The beam forms cavitations, microbubbles of carbon dioxide, and water vapor by photodisruption, and the interconnecting series of these bubbles forms a dissection plane. An inner diameter of 5.0 mm and outer diameter of 5.7 mm was programmed with the laser software, giving a tunnel width of 0.7 mm (the same as the segment width) and an incision length of 1.4 mm on the steepest topographic axis. In all eyes, the power used to create the tunnel and the incision was 5 mJ. The procedure lasted approximately 15 seconds.

Five minutes later and after clearance of the gas bubbles, the ICRS were implanted under full aseptic conditions with a dedicated forceps. The segments were placed in final position with a Sinsky hook through a dialing hole at both ends of the segment.

Postoperative treatment included tobramycin (3 mg/mL)-dexamethasone (1 mg/mL) eyedrops (TobraDex) 3 times daily for 2 weeks, after which the dose was tapered over 2 weeks.

Phakic Intraocular Lens Phakic IOL implantation was performed 6 months after ICRS implantation through a 3.2 mm clear corneal tunnel incision in the steepest meridian. The pIOL power was calculated using the manufacturer's software. In cases of bilateral pIOL implantation, the second eye was operated on within the first week of the first eye. Laser iridotomy was performed 1 week before the surgery.

Thirty minutes before surgery, cycloplegic and phenylephrine eyedrops were instilled. Five minutes before surgery, povidone-iodine 5.0% (Betadine) was instilled. The same experienced surgeon (J.F.A.) performed all pIOL

Submitted: July 12, 2010.

Final revision submitted: October 27, 2010.

Accepted: October 29, 2010.

From Fernández-Vega Ophthalmological Institute (Alfonso, Lisa, Fernández-Vega, Madrid-Costa, Poo-López), the Surgery Department (Alfonso, Fernández-Vega), School of Medicine, University of Oviedo; (Madrid-Costa, Montés-Micó), Faculty of Physics, University of Valencia, Valencia, Spain.

Corresponding author: José F. Alfonso, MD, PhD, Instituto Oftalmológico Fernández-Vega, Avenida Doctores Fernández-Vega 34, 33012 Oviedo, Spain. E-mail: j.alfonso@fernandez-vega.com.

implantations using peribulbar anesthesia. The anterior chamber was filled with sodium hyaluronate 1.0% (Provisc). After the pIOL was placed in the posterior chamber, the remaining ophthalmic viscosurgical device was washed from the anterior chamber with a balanced salt solution and acetylcholine chloride was instilled into the eye. Tobramycin and dexamethasone 0.1% eyedrops were used 4 times a day for 10 days, after which diclofenac sodium eyedrops (Voltaren) were started 4 times a day for 2 weeks. In eyes with astigmatism less than 1.25 D, 1 clear corneal incision (CCI) was created on the steepest meridian. In eyes with astigmatism higher than 1.50 D, 2 opposite CCIs (3.2 mm) were created on the steepest meridian and at 90 degrees after pIOL implantation to reduce the astigmatism, as previously reported in phacoemulsification.¹³ All incisions were performed with a 3.2 mm bevel-up steel blade (Equipisa S.A.) and were approximately 1.0 mm from the limbus.

Postoperative Examination

Patients were scheduled for postoperative clinical evaluation at 1 day, 1 week, and 1 and 6 months. A standard ophthalmologic examination, including manifest refraction, slitlamp biomicroscopy, Goldmann applanation tonometry, binocular indirect ophthalmoscopy, UDVA, and CDVA, was performed at all visits. All examinations were performed by the same ophthalmic technician who was unaware of the objective of the study.

Using the power vector method of Thibos and Horner,¹⁴ the refractions obtained before surgery, 6 months after ICRS implantation, and 6 months after pIOL implantation were assessed. Using this notation, any spherocylindrical refractive error can be expressed by 3 dioptric powers: M, J0, and J45, where M is a spherical lens equal to the SE of the given refractive error and J0 and J45 are 2 Jackson cross-cylinders equivalent to the conventional cylinder. These numbers are the coordinates of a point in a 3-dimensional dioptric space, being the power vector the vector from the origin of the 3-dimensional dioptric space (M, J0, J45). Thus, the length of this vector is a measure of the overall blurring strength (B) of a spherocylindrical refractive error. Manifest refractions in conventional script notation (S [sphere], C [cylinder] × φ [axis]) were converted to power vector coordinates and overall blurring strength (B) using the following formulas: $M = S + C/2$; $J0 = (-C/2) \cos(2\alpha)$; $J45 = (C/2) \sin(2\alpha)$; and $B = (M^2 + J0^2 + J45^2)^{1/2}$.

Statistical Analysis

Data analysis was performed using SPSS for Windows software (version 14.0, SPSS, Inc.). Normality was checked using the Kolmogorov-Smirnov test, and outcomes were compared using *t* tests. Differences were considered statistically significant when the *P* value was less than 0.01.

RESULTS

This study comprised 40 eyes of 31 patients (19 men, 12 women) with a mean age of 38 years ± 5.19 (SD). Table 1 shows the patients' demographics.

Figure 1 shows the efficacy of the ICRS and pIOL procedures. The mean UDVA (decimal) was 0.11 ± 0.05 Snellen before ICRS implantation, 0.18 ± 0.14 Snellen 6 months after ICRS implantation (before

Table 1. Patient demographics.

Parameter	Result
Sphere (D)	
Mean ± SD	-7.56 ± 7.27
Range	+3.25, -30.00
Cylinder (D)	
Mean ± SD	-4.19 ± 2.08
Range	-1.00, -8.00
K1 (D)	
Mean ± SD	45.03 ± 3.33
Range	40.00, 50.00
K2 (D)	
Mean ± SD	48.95 ± 4.77
Range	42.25, 55.00

K = keratometry

pIOL implantation) ($P = .001$), and 0.48 ± 0.24 Snellen 1 month after pIOL implantation with corneal relaxing incisions ($P < .0001$). There was no statistically significant difference in UDVA between 1 month and 6 months (mean 0.50 ± 0.27 Snellen) after pIOL implantation ($P = .29$). The mean CDVA was 0.56 ± 0.23 Snellen before ICRS implantation, 0.68 ± 0.25 Snellen 6 months after ICRS implantation ($P < .0001$), and 0.71 ± 0.19 Snellen 1 month after pIOL implantation with corneal relaxing incisions ($P < .0001$). There was no statistically significant difference in CDVA between 1 month and 6 months (mean 0.73 ± 0.20 Snellen) after pIOL implantation ($P < .0001$). The efficacy index (mean postoperative UDVA/mean preoperative CDVA) 6 months after ICRS implantation was 0.32

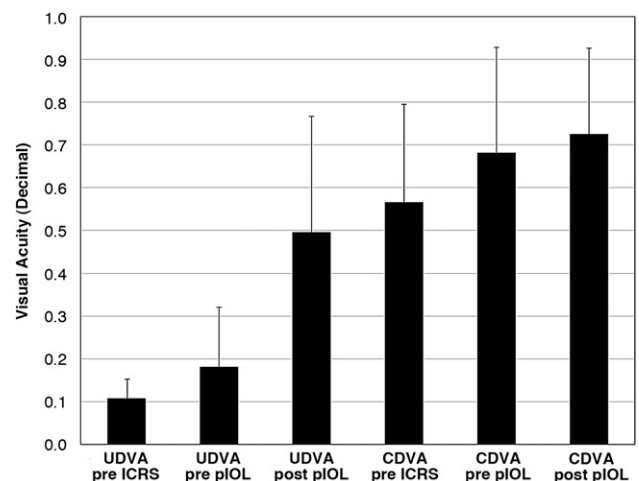


Figure 1. The UDVA and CDVA before, 6 months after ICRS implantation and 6 months after pIOL implantation with corneal relaxing incisions (efficacy) (CDVA = corrected distance visual acuity; ICRS = intrastromal corneal ring segment; pIOL = phakic intraocular lens; UDVA = uncorrected distance visual acuity).

and 6 months after pIOL implantation with corneal relaxing incisions, 0.88.

One eye lost more than 2 lines of CDVA 6 months after ICRS implantation; no eye lost more than 2 lines 6 months after pIOL implantation with corneal relaxing incisions (Figure 2). By 6 months after ICRS implantation, 4 eyes had lost 1 line of monocular CDVA, 9 eyes had no change, 9 eyes gained 1 line, 9 eyes gained 2 lines, and 8 eyes gained more than 2 lines. The safety index (ratio of postoperative to preoperative monocular CDVA) 6 months after ICRS implantation was 1.21. By 6 months after pIOL implantation, 3 eyes had lost 1 line of monocular CDVA, 9 eyes had no change, 7 eyes gained 1 line, 10 eyes gained 2 lines, and 11 eyes gained more than 2 lines. The safety index 6 months after pIOL implantation was 1.28.

Table 2 shows the distribution of manifest refractive error (power vector method) preoperatively, 6 months after ICRS implantation, and 6 months after pIOL implantation with corneal relaxing incisions. There was a statistically significant reduction in the B value after ICRS implantation as well as after pIOL implantation with corneal relaxing incisions (both $P < .0001$). There were no statistically significant differences in the M, J0, J45, or B value between 1 month and 6 months after pIOL implantation.

Figure 3 and Figure 4 show the attempted refraction versus the achieved refraction after ICRS implantation and after pIOL implantation with corneal relaxing incisions, respectively. A slight trend was found between the attempted change and the achieved change in M 6 months after ICRS implantation ($r = 0.43$; $P = .007$). For J0, 25 eyes (62.50%) were within ± 1.00 D

Table 2. Summary of distribution of manifest refractive errors (power vector method).

Value	Mean \pm SD		
	Before	After ICRS	After pIOL + CRI
M	-9.659 \pm 6.959*	-7.881 \pm 6.439 [†]	-1.198 \pm 1.326
J0	-1.153 \pm 1.118*	-0.679 \pm 0.548 [†]	-0.219 \pm 0.701
J45	0.251 \pm 1.706	0.109 \pm 0.681	0.020 \pm 0.659
B	10.292 \pm 6.409*	5.609 \pm 5.028 [†]	1.495 \pm 1.384

B = overall blurring strength; CRI = corneal relaxing incisions; ICRS = intrastromal corneal ring segment; J0 and J45 = jackson cross-cylinders equivalent to conventional cylinder; M is a spherical lens equal to spherical equivalent of given refractive error; pIOL = phakic intraocular lens
*Statistically significant between before ICRS insertion and after pIOL implantation
[†]Statistically significant between after ICRS implantation and after pIOL implantation

of the desired refraction and 15 eyes (37.50%) were within ± 0.50 D ($r = 0.75$; $P < .0001$). For J45, 37 eyes (92.50%) were within ± 1.00 D and 22 eyes (55%) were within ± 0.50 D ($r = 0.92$; $P < .0001$). Six months after pIOL implantation plus corneal relaxing incisions, for M, 26 eyes (65%) were within ± 1.00 D of the desired refraction and 18 eyes 45% were within ± 0.50 ($r = 0.98$; $P < .0001$). For J0, 37 eyes (92.50%) were within ± 1.00 D of the desired refraction and 29 eyes (72.50%) were within ± 0.50 D ($r = 0.80$; $P < .0001$). For J45, 34 eyes (85%) were within ± 1.00 D of the desired refraction and 33 eyes (82.50%) were within ± 0.50 D ($r = 0.92$; $P < .0001$).

Figure 5 shows the astigmatism component of the power vector represented by 2-dimensional vectors (J0, J45). The origin of the graph (0, 0) represents an eye free of astigmatism. The spread of the post ICRS implantation data from the origin is more concentrated than the spread of the preoperative data. The spread in the post ICRS implantation data was converted into a concentrated data set around the origin after pIOL implantation with corneal relaxing incisions.

DISCUSSION

The aim of ICRS implantation to treat keratoconus is to decrease corneal abnormalities and improve visual quality. The ICRS we used in this study, the Keraring, is a type of Ferrara segment that can be implanted more centrally than Intacs ICRS (Addition Technologies). In addition, Keraring ICRS have a triangular cross-section that induces a prismatic effect on the cornea. For both reasons, they might have a greater effect than Intacs ICRS.¹⁵ Previous studies⁵⁻⁷ report that Keraring ICRS implantation using a femtosecond laser for tunnel creation was minimally invasive, improved UDVA and CDVA, and

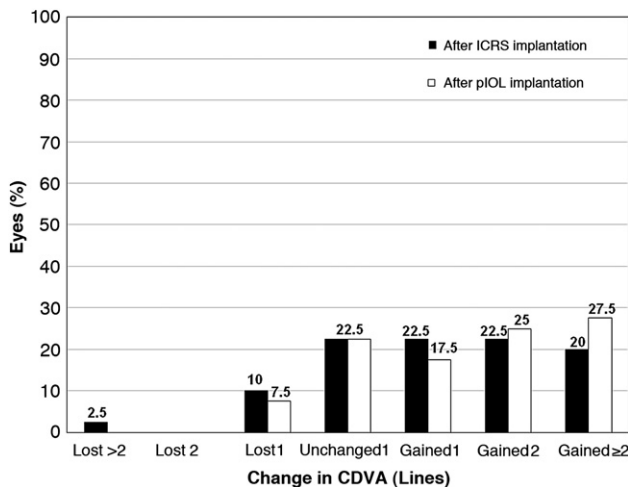


Figure 2. Change in CDVA 6 months after ICRS implantation and 6 months after pIOL implantation with corneal relaxing incisions (safety) (CDVA = corrected distance visual acuity; ICRS = intrastromal corneal ring segment; pIOL = phakic intraocular lens).

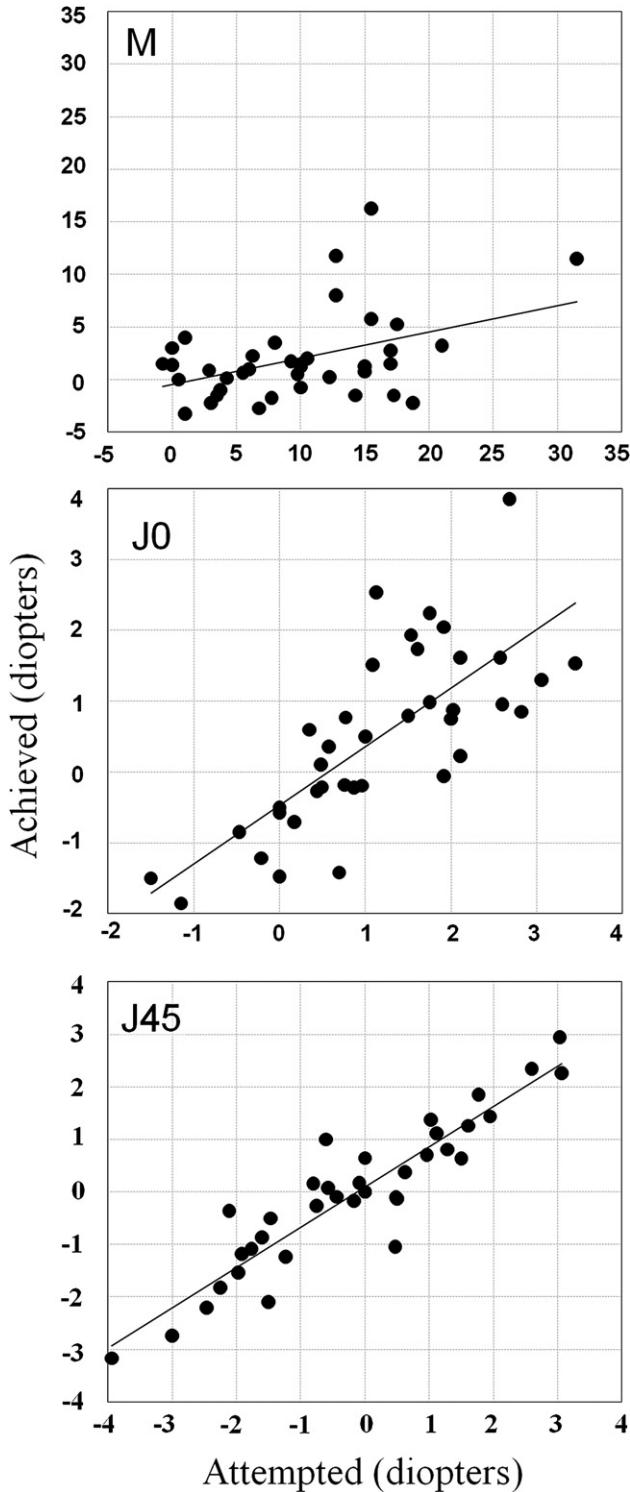


Figure 3. Attempted versus achieved SE (M) and the astigmatic components (J0 and J45) of the power vector analysis 6 months after ICRS insertion.

gave good refractive outcomes. Our results are in agreement; in our study, UDVA and CDVA improved after ICRS implantation and most eyes maintained or improved CDVA. Based on the safety

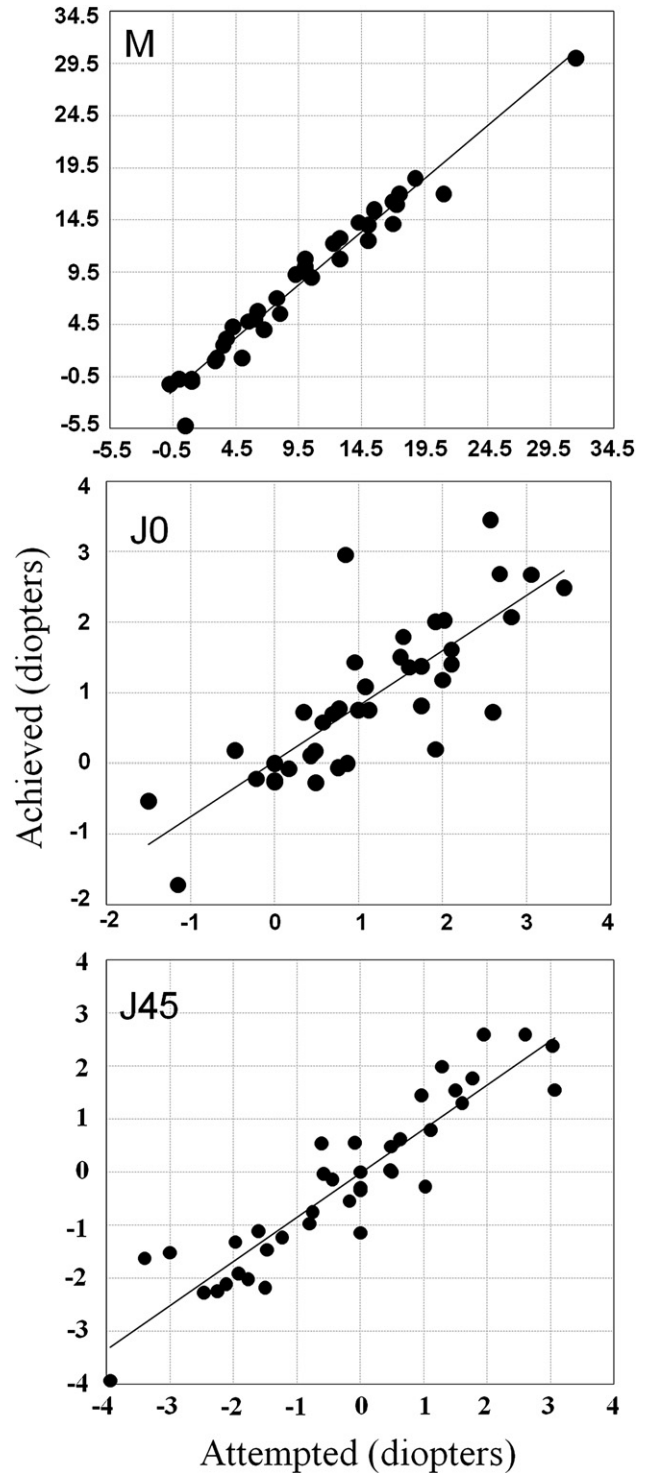


Figure 4. Attempted versus achieved SE (M) and the astigmatic components (J0 and J45) of the power vector analysis 6 months after pIOL implantation with corneal relaxing incisions.

index (1.21 6 months after ICRS implantation), the visual outcomes were satisfactory.

Regarding refractive outcomes, the preoperative astigmatism components (J0, J45) correlated highly

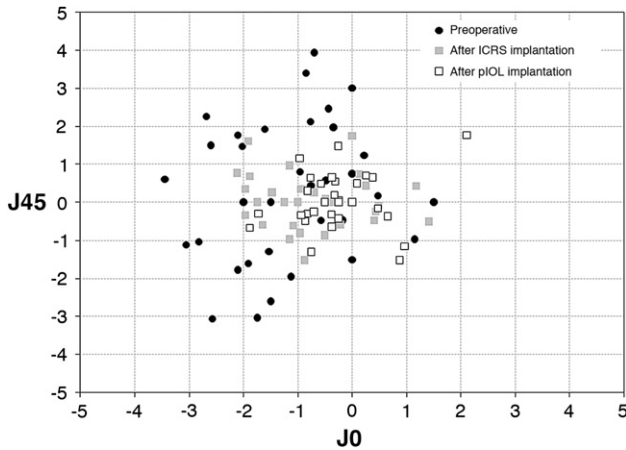


Figure 5. Representation of the astigmatic vectors (J0 and J45) before 6 months after ICRS implantation and 6 months after pIOL implantation with corneal relaxing incisions (ICRS = intrastromal corneal ring segment; pIOL = phakic intraocular lens).

with the amount of change in those components after ICRS implantation. There was a slight correlation between the attempted change and the achieved change in the M value 6 months after ICRS implantation. However, the M value after ICRS implantation was high (mean -7.881 ± 6.439 D), which may be why the efficacy index (mean postoperative UDVA/mean preoperative CDVA) 6 months after ICRS implantation was low (0.32). Preoperatively, most patients in our study had associated high ametropia. After ICRS implantation, the corneal shape improved; however, as shown in previous reports⁵⁻⁷ and as we found, patients may still have a significant degree of ametropia. Glasses or contact lenses can be used to compensate for the residual refractive error.¹⁶⁻¹⁸

In our prospective study, 40 eyes had implantation of a pIOL with corneal relaxing incisions to correct the residual refractive error after ICRS implantation. To our knowledge, there are no reports of sequential Keraring ICRS and Implantable Collamer Lens pIOL implantation plus corneal relaxing incisions for keratoconus correction.

In the present study, the UDVA improved significantly after pIOL implantation with corneal relaxing incisions. The efficacy index also improved after pIOL implantation (0.32) over the index after ICRS implantation (0.88). This is because the blur strength was significantly less after pIOL implantation with corneal relaxing incisions. The visual outcomes after this sequential procedure were satisfactory based on the safety index (1.28), with most of the eyes maintaining or improving CDVA; only 3 eyes lost 1 line of CDVA.

Predictability was also good after pIOL implantation with corneal relaxing incisions; 65% of eyes were within ± 1.00 D of the attempted SE (M). Most patients were within ± 1.00 D of the attempted

astigmatism components (J0, J45). In Figure 5, the spread of the post-pIOL implantation data is more concentrated around the origin of the graph (0, 0; representing an eye free of astigmatism) than after ICRS implantation. The reason is that after pIOL implantation, the clear corneal relaxing incisions were created on the steepest meridian in eyes with astigmatism. This suggests that such clear corneal relaxing incisions can compensate for residual astigmatism after ICRS implantation, although this should be confirmed in follow-up studies because the incision could also undermine the effect of the ICRS. Therefore, further studies of the astigmatism component over time after clear corneal relaxing incisions to correct astigmatism after ICRS implantation should be performed to confirm our findings.

We could make no direct comparisons with previous studies of sequential Keraring ICRS and posterior chamber Implantable Collamer Lens pIOL implantation with corneal relaxing incisions because to our knowledge, ours is the first study to evaluate this procedure. However, 2 previous studies evaluated pIOL implantation after ICRS insertion.^{19,20} El-Raggal and Abdel Fattah¹⁹ report results in 8 keratoconic eyes that had sequential insertion of Intacs ICRS and a Verisyse pIOL (Abbott Medical Optics, Inc.). As in the present study, the study by El-Raggal and Abdel Fattah¹⁹ found an improvement in UDVA and CDVA after pIOL implantation. There was also a significant reduction in the mean SE after pIOL implantation; however, the mean cylinder error increased. In our study, the cylinder error decreased after pIOL implantation with corneal relaxing incisions and the reduction in astigmatism was satisfactory. The difference in results is because the pIOL we used can be implanted through a small (3.2 mm) CCI; however, the Verisyse pIOL is not foldable and was implanted through a 6.5 mm superior CCI. On the other hand, we performed anti-astigmatic clear corneal relaxing incisions after pIOL implantation to compensate for the astigmatism.

Coskunseven et al.²⁰ report the results in 3 eyes of 2 consecutive highly myopic keratoconic patients who had implantation of a posterior chamber toric Implantable Collamer Lens pIOL after Intacs ICRS insertion. They found an improvement in UDVA and CDVA and a reduction in SE and cylinder error after toric pIOL implantation. The authors conclude that ICRS implantation and posterior chamber toric pIOL implantation in a 2-step procedure is an effective method for correcting keratoconus in the presence of high myopia.

Taking into account previous studies and our study, one may argue that anterior or posterior pIOLs are a viable option to correct the residual refractive error

after ICRS implantation in keratoconic eyes. Toric IOLs and opposite clear corneal relaxing incisions after pIOL implantation may reduce the cylindrical component in these cases. Differences between anterior pIOLs and posterior pIOLs have been widely described, as have the respective complications.²¹

The success of our sequential procedure requires knowledge of when the refraction is stable after ICRS insertion and whether the progression of keratoconus is halted because keratoconus progression leading to a refractive change can be a problem after pIOL implantation. A previous study²² evaluated the long-term results and stability of Intacs ICRS implantation for keratoconus correction. The authors found that CDVA stability was achieved, with no significant differences in refraction from 6 to 36 months after ICRS implantation; there was also an improvement in corneal topography. However, there was a significant increase in K values over time. Further long-term studies with a large sample and with different keratoconus stages should be performed to assess the stability of Keraring ICRS implantation for keratoconus correction.

Corneal collagen crosslinking (CXL) was introduced to slow the progression of keratoconus.^{23–27} Caporossi et al.²⁸ suggest that CXL may be most beneficial in young patients, especially those younger than 26 years with clinical and instrument-documented evidence of keratoconus progression and biomicroscopic evidence of a clear cornea. In our study, the mean age of the patients was 38 ± 5.19 years (range 27 to 44 years); therefore, we determined that corneal CXL should not be used as the first treatment option in our study. On the other hand, Hafezi et al.²⁹ studied the effect of corneal CXL with riboflavin and ultraviolet A on the optical and material characteristics of the posterior chamber Implantable Collamer Lens pIOL and found that the technique did not affect the optical or material characteristics of the pIOL. Therefore, corneal CXL could be considered when progression of keratoconus does not cease after ICRS and pIOL implantation.

In our study, no complications occurred during surgery or over the entire follow-up. The use of the femtosecond laser to create the corneal tunnel made ICRS implantation safer and provided a significant reduction in complications (eg, segment extrusion) because of the precise depth of the implantation.^{3,5} Although there were no complications in any case, long-term, randomized, comparative, and prospective studies should be performed to assess this sequential procedure and its complications because the procedure could lead to corneal endothelial deterioration by surgical trauma or to early corneal decompensation from the pIOL.

In conclusion, our medium-term outcomes are encouraging, suggesting that sequential Keraring ICRS and Intraocular Collamer Lens pIOL

implantation with corneal relaxing incisions provides good visual and refractive outcomes. Our results also suggest the procedure is predictable for refractive correction of keratoconus.

REFERENCES

1. Krachmer JH, Feder RS, Belin MW. Keratoconus and related noninflammatory corneal thinning disorders. *Surv Ophthalmol* 1984; 28:293–322
2. Rabinowitz YS. Keratoconus. *Surv Ophthalmol* 1988; 42:297–319
3. Ertan A, Kamburoğlu G, Bahadır M. Intacs insertion with the femtosecond laser for the management of keratoconus; one-year results. *J Cataract Refract Surg* 2006; 32:2039–2042
4. Ertan A, Kamburoğlu G. Intacs implantation using a femtosecond laser for management of keratoconus: comparison of 306 cases in different stages. *J Cataract Refract Surg* 2008; 34:1521–1526
5. Coskunseven E, Kymionis GD, Tsiklis NS, Atun S, Arslan E, Jankov MR, Pallikaris IG. One-year results of intrastromal corneal ring segment implantation (KeraRing) using femtosecond laser in patients with keratoconus. *Am J Ophthalmol* 2008; 145:775–779
6. Shabayek MH, Alió JL. Intrastromal corneal ring segment implantation by femtosecond laser for keratoconus correction. *Ophthalmology* 2007; 114:1643–1652
7. Torquetti L, Berbel RF, Ferrara P. Long-term follow-up of intrastromal corneal ring segments in keratoconus. *J Cataract Refract Surg* 2009; 35:1768–1773
8. Alfonso JF, Palacios A, Montés-Micó R. Myopic phakic STAAR collamer posterior chamber intraocular lenses for keratoconus. *J Refract Surg* 2008; 24:867–874
9. Maeda N, Klyce SD, Smolek MK. Comparison of methods for detecting keratoconus using videokeratography. *Arch Ophthalmol* 1995; 113:870–874
10. Rabinowitz YS, Rasheed K, Yang H, Elashoff J. Accuracy of ultrasonic pachymetry and videokeratography in detecting keratoconus. *J Cataract Refract Surg* 1998; 24:196–201
11. Fam H-B, Lim K-L. Corneal elevation indices in normal and keratoconic eyes. *J Cataract Refract Surg* 2006; 32:1281–1287
12. Quisling S, Sjöberg S, Zimmerman B, Goins K, Sutphin J. Comparison of Pentacam and Orbscan IIz on posterior curvature topography measurements in keratoconus eyes. *Ophthalmology* 2006; 113:1629–1632
13. Tadros A, Habib M, Tejwani D, Von Lany H, Thomas P. Opposite clear corneal incisions on the steep meridian in phacoemulsification: early effects on the cornea. *J Cataract Refract Surg* 2004; 30:414–417
14. Thibos LN, Horner D. Power vector analysis of the optical outcome of refractive surgery. *J Cataract Refract Surg* 2001; 27:80–85
15. Kubaloglu A, Cinar Y, Sari ES, Koytak A, Ozdemir B, Ozertürk Y. Comparison of 2 intrastromal corneal ring segment models in the management of keratoconus. *J Cataract Refract Surg* 2010; 36:978–985
16. Nepomuceno RL, Boxer Wachler BS, Weissman BA. Feasibility of contact lens fitting on keratoconus patients with INTACS inserts. *Cont Lens Anterior Eye* 2003; 26:175–180
17. Uçakhan ÖÖ, Kanpolat A, Özdemir Ö. Contact lens fitting for keratoconus after Intacs placement. *Eye Contact Lens* 2006; 32:75–77
18. Hladun L, Harris M. Contact lens fitting over intrastromal corneal rings in a keratoconic patient. *Optometry* 2004; 75:48–54
19. El-Raggal TM, Abdel Fattah AA. Sequential Intacs and Verisyse phakic intraocular lens for refractive improvement in keratoconic eyes. *J Cataract Refract Surg* 2007; 33:966–970

20. Coskunseven E, Onder M, Kymionis GD, Diakonis VF, Arslan E, Tsiklis N, Bouzoukis DI, Ioannis Pallikaris I. Combined Intacs and posterior chamber toric implantable Collamer lens implantation for keratoconic patients with extreme myopia. *Am J Ophthalmol* 2007; 144:387–389
21. van der Heijde GL. Some optical aspects of implantation of an IOL in a myopic eye. *Eur J Implant Refract Surg* 1989; 1:245–248
22. Alió JL, Shabayek MH, Artola A. Intracorneal ring segments for keratoconus correction: long-term follow-up. *J Cataract Refract Surg* 2006; 32:978–985
23. Spoerl E, Huhle M, Seiler T. Induction of cross-links in corneal tissue. *Exp Eye Res* 1998; 66:97–103
24. Wollensak G, Spoerl E, Seiler T. Riboflavin/ultraviolet-A-induced collagen crosslinking for the treatment of keratoconus. *Am J Ophthalmol* 2003; 135:620–627
25. Spoerl E, Wollensak G, Seiler T. Increased resistance of cross-linked cornea against enzymatic digestion. *Curr Eye Res* 2004; 29:35–40
26. Spörl E, Raiskup-Wolf F, Pillunat LE. Biophysikalische Grundlagen der Kollagenvernetzung [Biophysical principles of collagen cross-linking]. *Klin Monatsbl Augenheilkd* 2008; 225:131–137
27. Caporossi A, Baiocchi S, Mazzotta C, Traversi C, Caporossi T. Parasurgical therapy for keratoconus by riboflavin-ultraviolet type A rays induced cross-linking of corneal collagen; preliminary refractive results in an Italian study. *J Cataract Refract Surg* 2006; 32:837–845
28. Caporossi A, Mazzotta C, Baiocchi S, Caporossi T. Long-term results of riboflavin ultraviolet A corneal collagen cross-linking for keratoconus in Italy: the Siena Eye Cross Study. *Am J Ophthalmol* 2010; 149:585–593
29. Hafezi F, Majo F, El Danasoury AM. Effect of the direct application of riboflavin and UVA on the Visian Implantable Collamer Lens. *J Refract Surg* 2010; 26:762–765



First author:

José F. Alfonso, MD, PhD

*Surgery Department, School of
Medicine, University of Oviedo,
Oviedo, Spain*